



Dossier 6

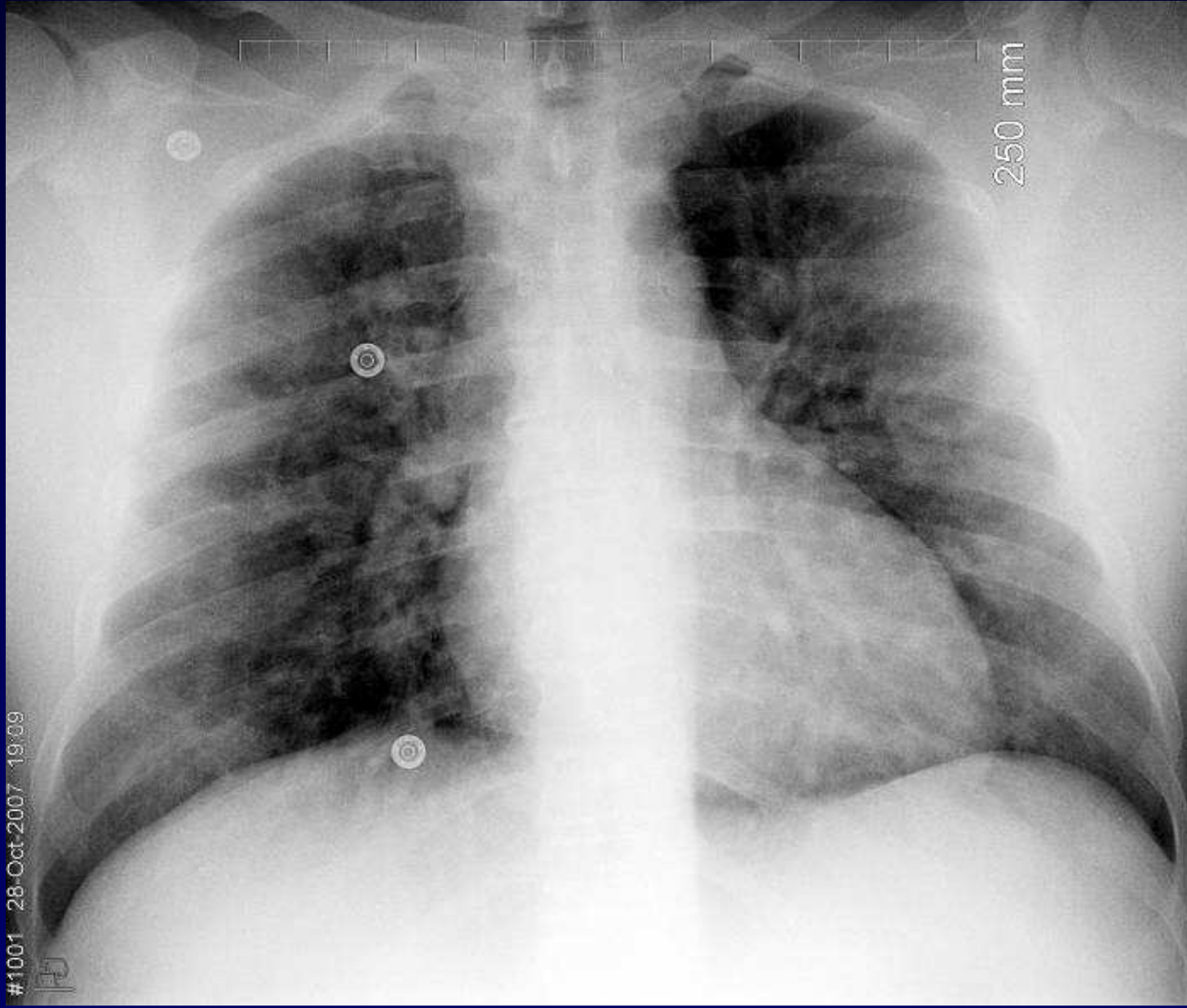
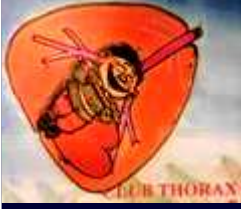**J. GIRON
P. FAJADET**

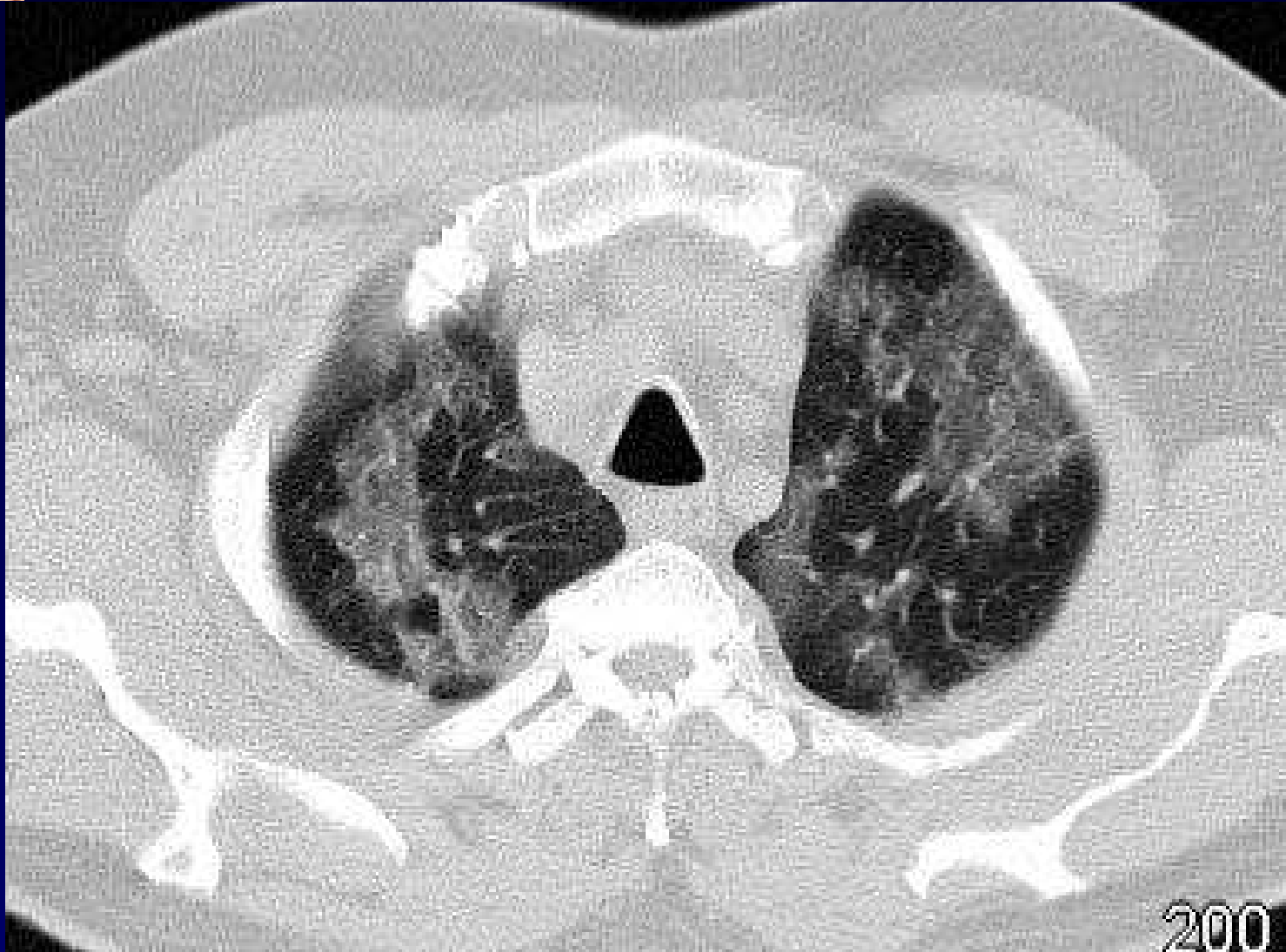
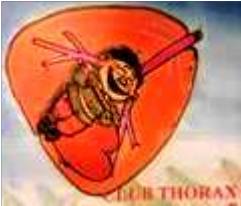Homme de 42 ans

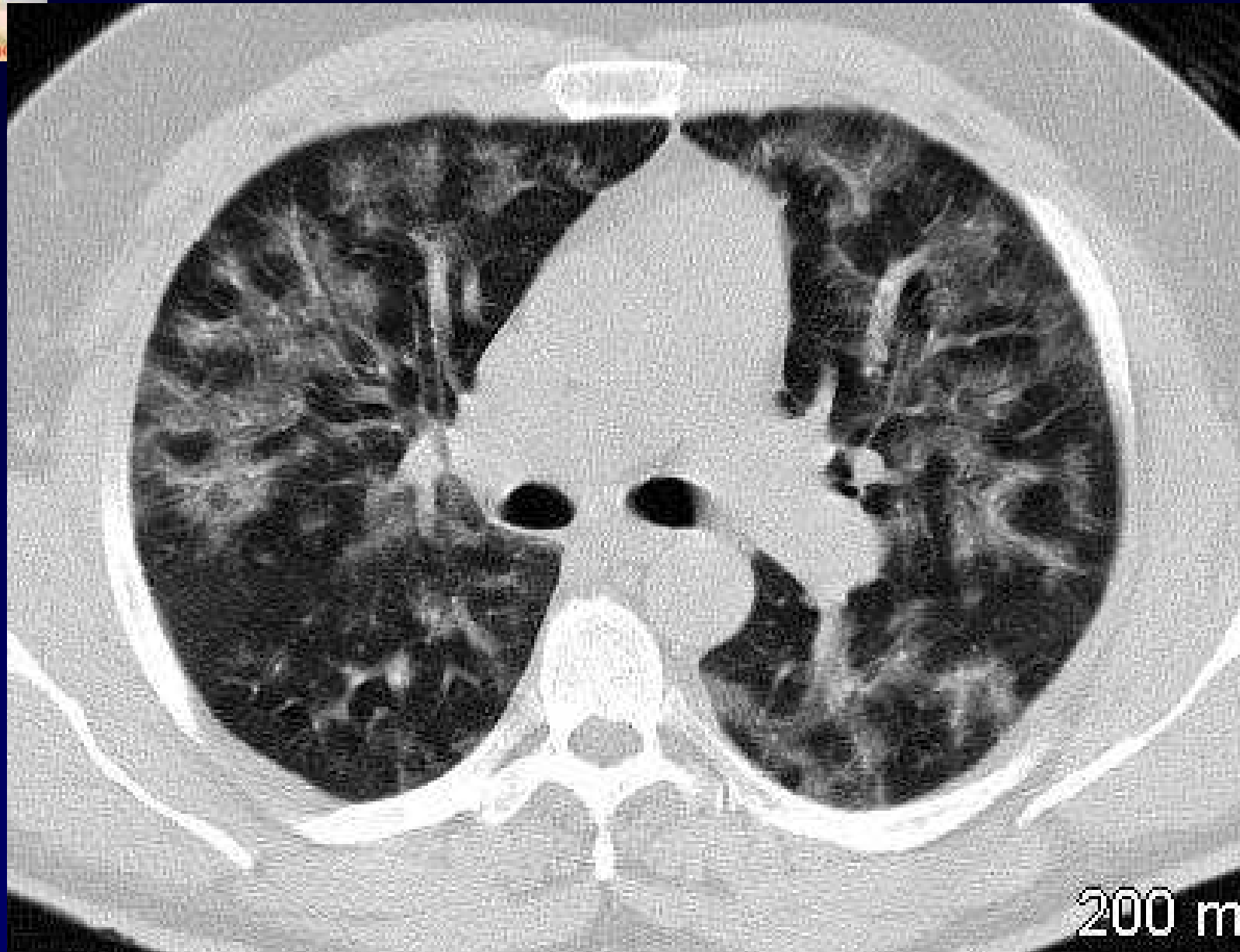
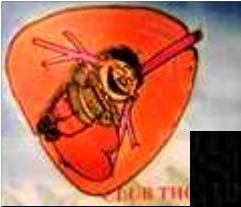
Ictère , cytolyse

Echographie hépatique normale

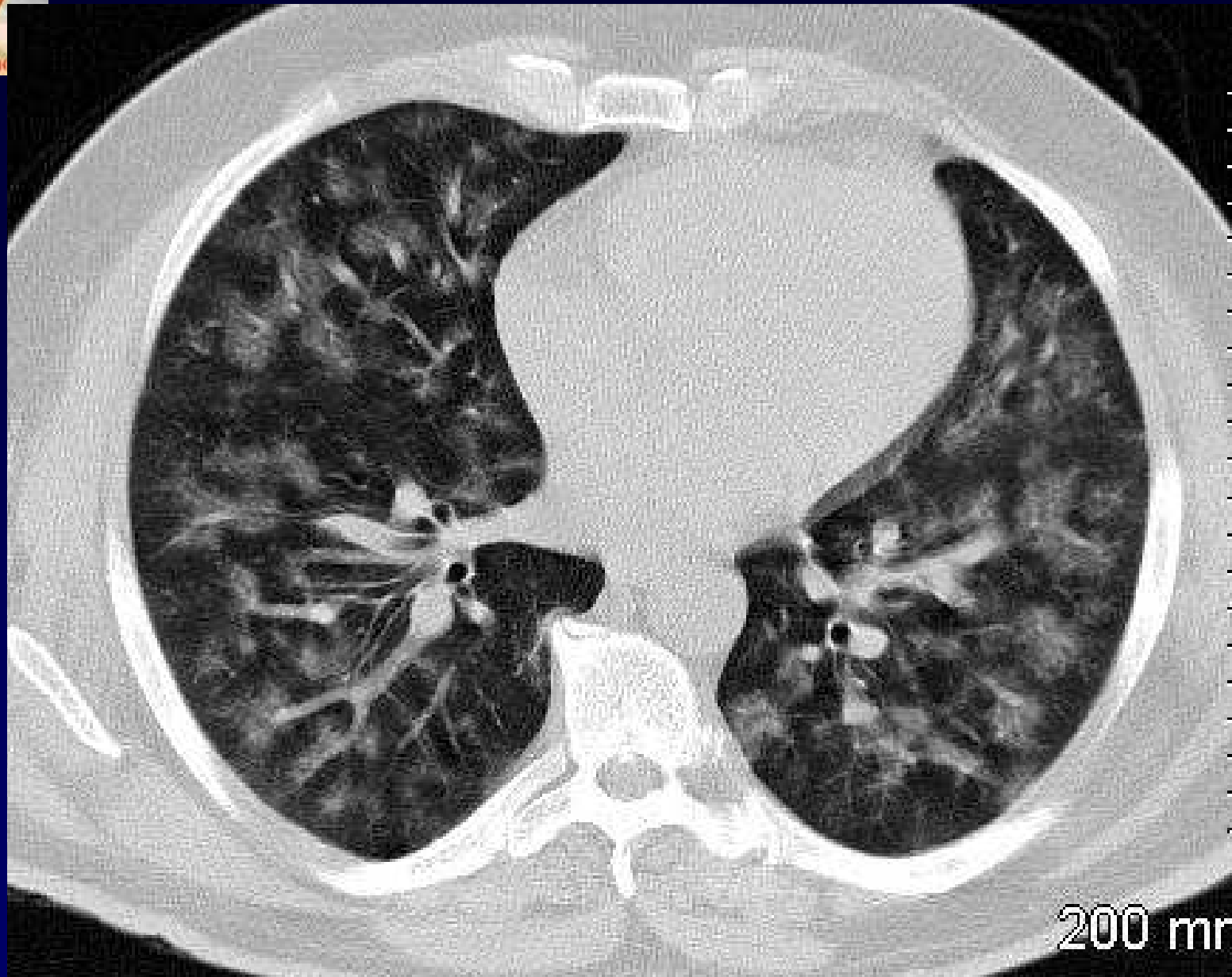
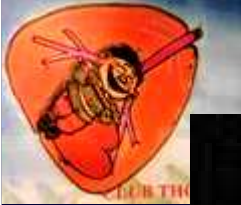Crachats hémoptoïques



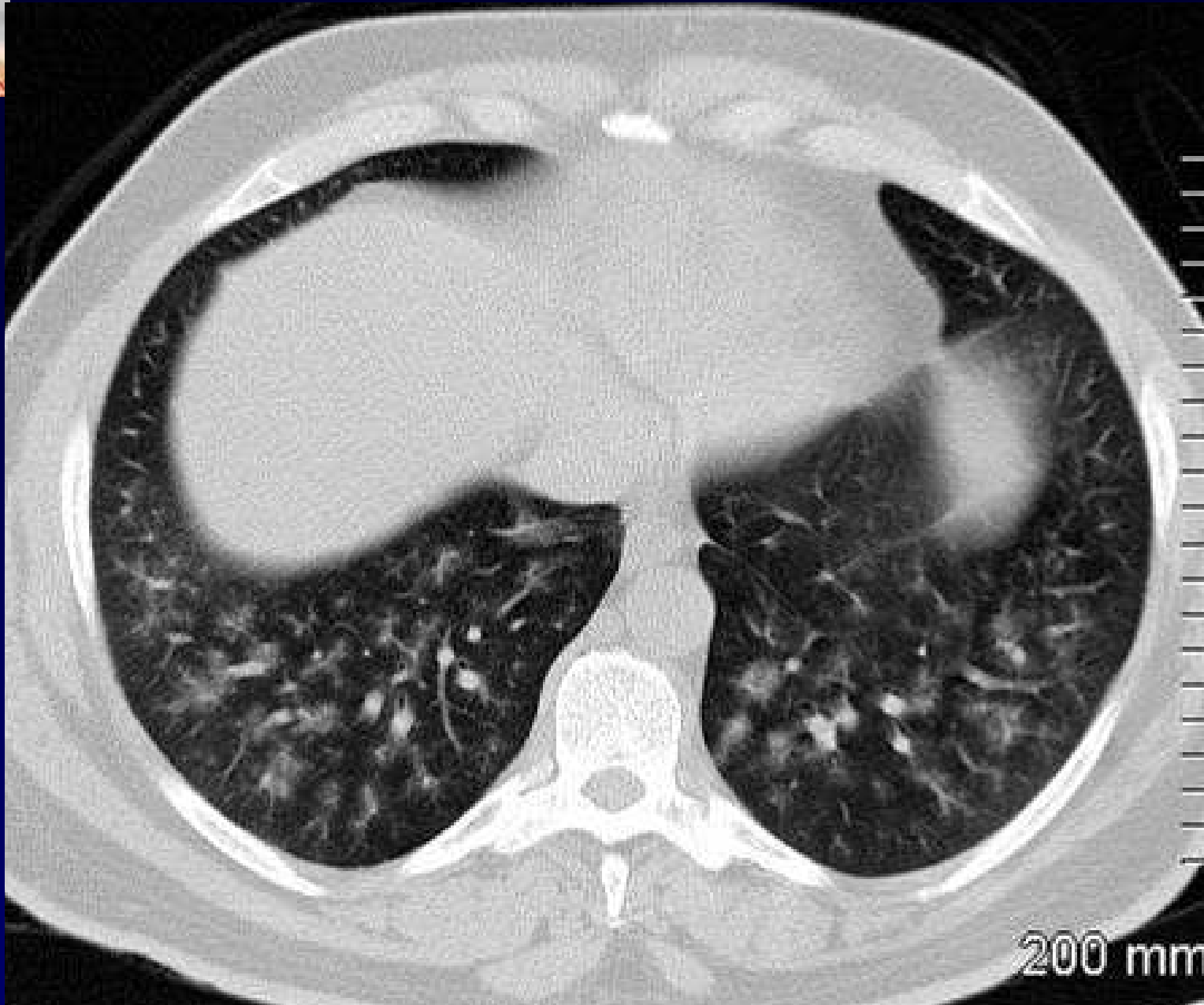
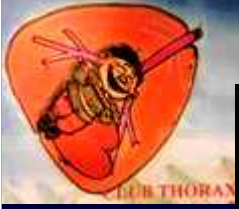



200 mm



200 mm



200 mm



Diagnostic ?



Diagnostic ?

Leptospirose ictère-hémorragique : LIH

Codage : Poumon - Infectieux



Références

Pub Med = « Pulmonary Leptospirosis Imaging »

1- Barroso-Pereira JC

Pulmonary Leptospirosis

Rev. Port. Pneumol 2007 nov-déc

2- Henk .CB-/Schoder-M/ Bankier AA

Weil disease : importance of imaging findings for early diagnosis

J Comput-Assist-Tomogr 1996 jul-aug 20 (4) : 609-12